



REVIEW

Cervical lymph node dissection in papillary thyroid cancer: Current trends, persisting controversies, and unclarified uncertainties

George H. Sakorafas*, Dimitrios Sampanis, Michael Safioleas

4th Department of Surgery, Athens University, Medical School Attikon University Hospital, Arkadias 19-21, GR-115 26, Athens, Greece

Accepted 1 April 2009

KEYWORDS

Thyroid;
Surgery;
Papillary;
Lymph node metastases;
Node dissection;
Recurrence;
Differentiated thyroid cancer;
Survival;
Micrometastases;
Complications;
Thyroidectomy

Abstract

Cervical lymph node metastases are very common in patients with papillary thyroid cancer (PTC). Despite that PTC has an excellent prognosis, lymphatic spread is associated with increased risk of loco-regional recurrence, which significantly impairs quality-of-life and can alter prognosis of the patient. Therefore, the identification of lymph node metastases preoperatively is very important for the surgeon to plan the optimal surgical therapy for the individual patient. In most western countries, cervical lymph node dissection (CLND) is performed in the presence of cervical lymphadenopathy (therapeutic CLND). In contrast, in eastern countries (mainly in Japan, where the use of postoperative radioiodine adjuvant therapy is restricted by law), most surgeons perform prophylactic CLND (i.e., CLND in the absence of cervical lymphadenopathy). CLND is performed on a compartment-oriented basis. Currently, given the very high incidence of cervical lymph node metastases in PTC, there is a clear trend—even in western countries—in favor of central (level IV) node dissection, even in patients without clinically or ultrasonographically evident node disease. This surgical strategy will prevent disease recurrence, which may require an additional and more morbid surgery. Experience is therefore required from the part of the operating surgeon, who should be able to perform safely CLND at the time of initial surgery (thyroidectomy), to minimize surgical morbidity.

© 2009 Published by Elsevier Ltd.

Abbreviations: PTC, Papillary thyroid cancer; CLND, Cervical lymph node dissection; PTMC, Papillary thyroid microcarcinoma; RLN, Recurrent laryngeal nerve.

* Corresponding author. Tel./fax: +30 (210) 74 87 192.

E-mail address: georgesakorafas@yahoo.com (G.H. Sakorafas).

Contents

Introduction e58
The extend of the problem e59

Biologic behavior and clinical significance of cervical lymph node metastases/micrometastases in PTC	e59
Applied surgical anatomy; lymph node compartments and pattern of lymph node metastasis	e60
Types of cervical lymph node dissection	e61
Radical neck dissection	e61
Extended radical neck dissection	e61
Modified radical neck dissection	e61
Selective neck dissection	e62
Berry picking	e62
Surgical strategy	e62
Elective vs. routine CLND	e62
Elective or therapeutic CLND	e62
Routine or prophylactic CLND	e62
Practical considerations	e63
Preoperative investigation/documentation	e63
Incision and access	e63
Management of parathyroids	e63
Extent of CLND	e63
The role of contralateral neck dissection	e64
What's the role of CLND in microscopic metastatic spread?	e64
Complications	e64
Hypoparathyroidism	e65
Recurrent laryngeal nerve injury	e65
Thoracic duct injury	e65
Neck anesthesia/neuropathic pain/decreased shoulder mobility	e65
Other complications	e65
Newer surgical approaches	e65
Video-assisted technique	e65
Sentinel lymph node dissection	e66
Postoperative management	e66
TSH suppression	e66
Radioactive iodine therapy (RIT)	e67
Conflict of interest statement	e67
Authorship	e67
References	e67

Introduction

Papillary thyroid cancer (PTC) is the most common type of thyroid cancer, representing about 75% of all thyroid malignancies and more than 90% of differentiated thyroid cancer [1,2]. The optimal strategy for treatment of patients with PTC combines complete surgical resection of clinically and radiologically evident disease within the neck, appropriate use of radioiodine ablation (RIA) (when indicated), and postoperative TSH suppression. PTC shows a mild biological behavior and has an excellent prognosis. Adequate management leads to a survival rate of excess of 90%. Death by PTC is very rare [3]. However, cervical lymph node metastases are common in PTC and are associated with a significant probability for loco-regional recurrence of the disease, even in low-risk patients. As a result, a rapid shift in patient care from a focus on overall survival to a focus on recurrence-free survival has recently noted. These considerations generated a strong interest in a more comprehensive preoperative evaluation of the neck and renewed the controversy about the role and the extent of lymphadenectomy at the time of thyroidectomy [4]. Preoperative

identification of cervical lymph node metastases may be a problem, despite recent progress and continuous improvement of diagnostic modalities used in the preoperative investigation of thyroid diseases. Moreover, many questions remain unanswered regarding the optimal management of patients with cervical lymph node metastases. In selecting the optimal management, an in-depth understanding of the biological behavior of cervical lymph node metastases is required. Ideally, surgical treatment should be radical enough in order to achieve complete eradication of the disease, while—at the same time—minimizing treatment and disease-related morbidity. To eliminate the probability of leaving behind residual disease, routine total thyroidectomy with cervical lymph node dissection (CLND) would be theoretically the ideal operation. However, such an aggressive surgical approach will represent over-treatment in a large percentage of patients, associated with an unjustified increase of surgical morbidity.

The aim of this paper is to critically summarize currently available data regarding the optimal treatment of patients with PTC with a particular emphasis on the role of CLND.

Current controversies and recent trends are presented and extensively discussed in order to help the practicing surgeon to select the ideal operation for the individual patient with PTC.

The extend of the problem

In patients with PTC there is a high incidence of cervical lymph node metastasis at the time of primary diagnosis, depending not only on the actual pathological stage of the disease, but also on which diagnostic modalities are employed to assess the potential metastases [5–7]. Clinical examination may detect lymph node involvement in 15–30% of patients [8]. However, data from centers where routine CLND or sentinel lymph node biopsy (SLNB, see below) are practiced showed that occult metastases may be observed in up to 90% of patients [9–14]. Interestingly, for clinically node-negative PTC, lymph node metastases are found in 50–60% of the central lymph nodes [15]. Lymph node metastases occur in a significant percentage (ranging from 15% to 65%) of patients with papillary thyroid microcarcinoma (tumor <10 mm in diameter) (PTMC) [16–18]; this lymphatic spread in PTMC probably is responsible for a 5% lymph node recurrence rate, a 2.5% distant metastasis rate, and a 1% disease-related mortality rate [15,19,20]. Factors associated with lymph node metastasis in PTMC patients include tumor size (>5 mm), extracapsular invasion, and multifocality [19,20–22].

Micrometastases (defined as the presence of metastatic deposits within a lymph node of less than 2 mm in diameter) are a very common and particular problem [23]. Unfortunately, many authors do not distinguish macro- and micrometastatic disease in their reports and this complicates the estimation of the true incidence of micrometastatic spread. Obviously, the reported rates of micrometastases in PTC vary with the technique used to detect them. Data specifically regarding micrometastatic spread are limited, and come mainly from centers where routine CLND is performed; these reports describe that lymph node micrometastases are observed in 53–66% of patients [24,25]. In an interesting study, Qubain et al. [24] described the pattern of micrometastatic spread in a cohort of 80 patients who underwent routine central and ipsilateral modified radical neck dissections. They examined a total of 2551 lymph nodes with immunohistochemistry (IHC) to identify all micrometastases and describe their distribution. In their study, even PTMC was associated with micrometastatic disease in 26%, while tumors greater than 10 mm were associated with micrometastases 66% of the time. Others, however, have reported that only 12% of patients had purely micrometastatic disease in isolation [26]. These authors have reported that the rate of patients with macroscopic metastases was more than double that of those with solely micrometastases (29% vs. 12%) [25].

Biologic behavior and clinical significance of cervical lymph node metastases/micrometastases in PTC

Despite the very high incidence of cervical lymph node metastases in PTC, the reported rates of loco-regional

recurrence range between 3% and 30% for low-risk PTC (Table 1) [27,28]. Even for high-risk cases (Table 1), the rates are only 59% often in patients with evidence of macroscopically involved nodes. These data indicate that the majority of lymph node metastases do not progress following initial treatment whether they are micrometastases or macrometastases. However, the presence of macrometastatic disease has been widely recognized as an independent risk factor for loco-regional recurrence in PTC [6,15,29–37]. Cervical recurrence occurs in up to 20% of patients with low-risk PTC and up to 60% of those with high-risk disease [29,32,38,39]. Prognosis for the development of loco-regional recurrences relies on other variables combined in a variety of prognostic algorithms [38,40,41]. Massive extrathyroid extension, male gender, and age 55 years or older have been associated with increased probability of disease recurrence [42]. Large tumor size is inversely associated with disease-free survival. Indeed, Ito et al. [42] recently reported that the 10-year lymph node-disease-free survival rate of patients with carcinoma larger than 3 cm was low at 87%, whereas that of patients with carcinoma <3 cm was as high as 97.5%.

Currently, despite some controversy [43–46], it is generally accepted that cervical lymph node involvement in PTC does not affect overall survival [29,30,32,33,39,40,47–49]. A negative impact of lymph node metastases on overall survival has been shown in some subgroups, such as elderly individuals or patients with bulky nodal disease

Table 1 Risk stratification systems for differentiated thyroid cancer.

Ages	Age Metastases Extent Size
AMES	Age Metastases Extent Size
MACIS	Metastases Age Completeness of resection
DAMES	Diploid Age Metastases Extent Size
GAMES	Grade Age Metastases Extent Size
TNM/UICC	Tumor size Nodal status Metastases

From Gosnell JE, Clark OH. Surgical approaches to thyroid tumors. *Endocrinol Metab Clin N Am* 2008;37:437–55.

[5,36,43,44,50–54]. Most authors agree that extended CLND does not significantly reduce overall survival of patients with PTC.

Despite that the role of lymph node metastases in defining prognosis (i.e., overall survival) currently remains relatively limited, the surgeon should recognize that local nodal recurrence is a significant problem for patients, associated with a poor prognosis and high morbidity and mortality rates, usually due to invasion of the trachea or the great vessels or to recurrent laryngeal nerve involvement [55]. Therefore, the impact of local recurrence on patient's quality-of-life is tremendous. Moreover, about 10% of patients with local recurrence and 50% of those with distant metastasis will die of the disease [39]. In these patients, reoperation is a traumatic event and may be associated with unacceptably high complication rates, such as injury to the recurrent laryngeal nerve, hypoparathyroidism, palsy of the spinal accessory nerve, and unsightly surgical scars (see below) [30,56]. For these reasons and because death is very uncommon in PTC [3], survival is no longer the outcome of interest in PTC; instead, loco-regional recurrence is used as a valid endpoint to evaluate the effectiveness of therapy for PTC. These data renewed the interest regarding the rates of local recurrence in PTC during the last decade.

Data regarding the biological behavior of micrometastatic disease are few. There is evidence that only a small proportion of microscopic metastases in PTC will become clinically apparent even over many years

[15,16,18–22]. Survival is not affected by the presence of micrometastases, and even rates of loco-regional recurrence are low, suggesting that micrometastatic deposits have little prognostic significance [25]. Therefore, patients with micrometastatic disease seem to have the same prognosis as patients without any metastatic disease.

Applied surgical anatomy; lymph node compartments and pattern of lymph node metastasis

The neck contains a very rich lymphatic network. Indeed, two-fifths of the body's lymph nodes are located in the head and neck region [57,58]. The thyroid gland has an extensive lymphatic drainage, which may follow a number of directions. Until the early 1990s, cervical lymph nodes classification was based on anatomic location, with the anterior nodal groups labeled as submental, submandibular, internal jugular, supraclavicular, posterior triangle, and parotid [59]. This classification was cumbersome and a better topographic classification was adapted to aid in mapping nodal surgical intervention. Nowadays, the most widely used classification system is based on recommendations by the American Joint Committee on Cancer (AJCC) and the American Academy of Otolaryngology – Head and Neck Surgery and uses landmarks from cross-sectional anatomic imaging [60–62] (Figure 1). This system is composed of six major nodal regions (I–VI) and defines

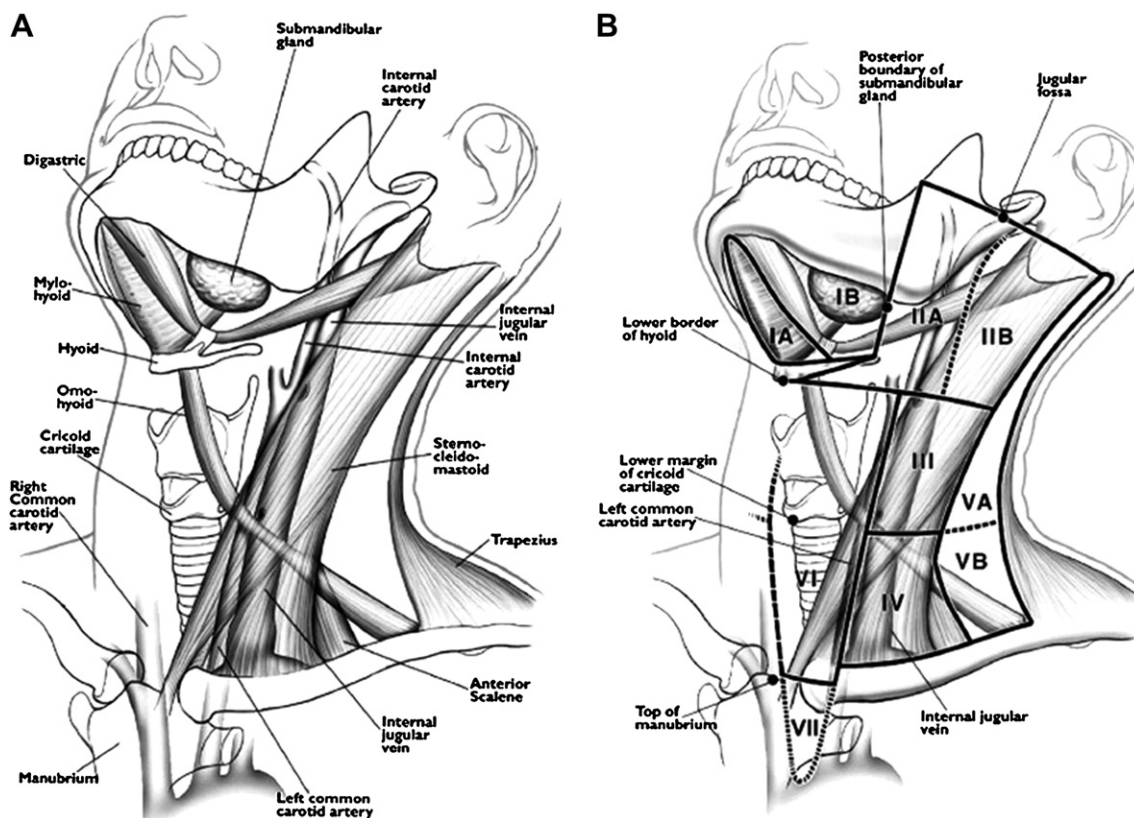


Figure 1 (A) Note the anatomic landmarks that are used to divide the lateral and central lymph node compartments into levels I–VI. (B) Lymph node mapping by levels, based on Cross-sectional imaging. However, lymph node mapping can be approximated by sonographic imaging and knowledge of the necessary anatomic landmarks. (From Ref. # [64]).

a compartment-oriented neck dissection. Sublevel classification is also used when certain zones within the larger levels have independent biological significance.

Level I lymph nodes are submental (sublevel IA) and submandibular (sublevel IB) and usually do not contain lymph node metastases from PTC.

Level II (upper jugular region) lymph nodes are located above the level of the hyoid bone to the base of skull; level IIA lymph nodes are located anterior (medial) to the vertical plane defined by the spinal accessory nerve and are often removed in a standard lateral neck dissection for thyroid cancer. Level IIB nodes are located posterior (lateral) to this vertical plane requiring a dissection that significantly manipulates the spinal accessory nerve.

Level III (middle jugular region) lymph nodes are located between the levels of the hyoid bone and the cricoid cartilage.

Level IV (lower jugular region) lymph nodes are below the level of the cricoid cartilage extending to the clavicle. The term '*lateral compartment*' includes levels II through level IV lymph nodes, which are found around the jugulocarotid vascular bundle and may be under the sternocleidomastoid muscle.

Level V lymph nodes are the posterior triangle group including the supraclavicular lymph nodes. This group is further divided into Level VA (lymph nodes located above the horizontal plane defined by the inferior border of the cricoid cartilage and includes the lymph nodes lying along the spinal accessory nerve) and level VB (lymph nodes located below the horizontal plane defined by the inferior border of the cricoid cartilage and includes the lymph nodes lying along the transverse cervical artery).

Level VI lymph nodes are included in the central (or anterior) compartment, posterior and inferior of the thyroid gland and adjacent to the trachea and esophagus; this compartment includes the pretracheal and paratracheal nodes, precricoid (Delphian) node, and the perithyroidal lymph nodes as well as the lymph nodes along the recurrent laryngeal nerves. Anatomically, the central or anterior compartment (level VI) is bounded by the medial carotid sheaths laterally, the hyoid bone superiorly, and the thoracic islet (sternal notch) inferiorly.

Level VII lymph nodes are the superior mediastinal lymph nodes. Preoperatively, some of these nodes may be imaged by ultrasound if the patient's neck is hyperextended.

Lymphatic metastasis from PTC occurs in a stepwise fashion: first to the lymph nodes in the ipsilateral tracheoesophageal groove, and, subsequently, to lymph nodes in the jugular chain, including the supraclavicular fossa [63,64]. Many groups have reported that the risk of lymphatic metastasis was greatest for the lateral nodal groups of levels II, III, and IV [6,7,15,64–69]. Central (level VI) lymph nodes are also involved at comparable rates (29% vs. 32% for central and lateral lymph nodes, respectively) [70], while bilateral lymph node metastases may be

observed in a significant percentage (up to 30%) of patients [70,71]. Other groups have reported that ipsilateral central neck is the most common site of metastatic PTC [6,7,24,67–69]. In fact, there is a significant level of co-existence of metastatic disease in the central and lateral compartments. Roh et al. have found that patients with lateral cervical metastases from PTC are also very likely to have clinically (86%) or pathologically (90%) positive central-neck disease [64]. It is also well recognized that both central and lateral disease can occur in isolation; indeed, multiple-level nodal involvement is commonly observed [24,68,70,72]. Metastases to the level V nodes may be observed in up to 20% of patients [64]. Level I disease is very rare [6,67], while only level I or V metastases (isolated metastases, without involvement at other levels) have not been reported [7,65].

Of note, tumor position within the thyroid correlates to some degree with the site of metastatic spread [24]. Tumors in the isthmus, middle and lower thirds more commonly metastasize to the central compartment, while tumors in the rest of the gland to the ipsilateral jugular nodes [24,60]. However, metastatic pathways are unpredictable, while in some cases the metastatic process 'skips' the predicted compartment. Usually the term 'skip' metastases describe lateral compartment disease in isolation (i.e., without central compartment involvement); 'skip' metastases were observed in about 20% of PTC in a retrospective review of patients undergoing routine central and lateral neck dissections [73].

Types of cervical lymph node dissection

To ensure accurate communication and adequate assessment of reported studies, the surgeon should have a clear understanding of the different types of CLND [74].

Radical neck dissection

This basic procedure was described in 1906 by George Grile and included removal of all the lymph nodes in the neck, along with three important anatomic structures – the sternocleidomastoid muscle, the internal jugular vein, and the spinal accessory nerve. Major drawbacks to this surgical procedure were dysmorphism and shoulder dysfunction due to sacrifice of the spinal accessory nerve (see below, complications).

Extended radical neck dissection

This is a more aggressive procedure than radical neck dissection, in which additional lymph node groups or non-lymphatic structures relative to the radical neck dissection are removed. Radical and extended radical neck dissection with sacrifice of uninvolved cervical structures in patients with PTC and regional metastatic disease are not indicated.

Modified radical neck dissection

This procedure was described as a 'functional neck dissection' in 1962 by Oswaldo Suarez, an Argentinian surgeon and

subsequently popularized in Europe by Ettore Bocca and Caesar Gavilan, and in the US by surgeons from the MD Anderson Hospital (Richard Jesse, Alando Ballantyne, and Robert Byers) [75]. The major pendulum swing from radical to modified neck dissection occurred in the early 80s. The surgical philosophy behind this procedure was to remove a selected group of lymph nodes and to preserve vital or important structures (such as the sternocleidomastoid muscle, internal jugular vein, carotid artery, vagus, phrenic, and spinal accessory nerve, along with the submandibular salivary gland), thereby minimizing morbidity [76]. Depending on which non-lymphatic structure is preserved, modified radical neck dissection is further subdivided into *type I* (preservation of the spinal accessory nerve), *type II* (preservation of the spinal accessory nerve and internal jugular vein), and *type III* (preservation of the spinal accessory nerve, internal jugular vein, and sternocleidomastoid muscle).

Selective neck dissection

In this type of surgery, one or more lymph node groups routinely removed in the radical neck dissection is preserved. Currently, most procedures are performed on a 'compartment-oriented' basis, based on different anatomical regional boundaries (see above). The term *central compartment dissection* describes removal of lymph nodes and soft tissues in level VI with preservation of the recurrent laryngeal nerves and at least the superior parathyroid glands. The term *lateral compartment dissection* refers to removal of all soft tissue and lymph nodes in levels IIA, III, IV and V [57]. In other words, in this procedure all the fibrofatty tissue (including lymph nodes) from the lateral wall of the carotid sheath to the trapezius muscle and from the subclavian vein inferiorly to the hypoglossal nerve superiorly is excised. Since the incidence of lymph node metastases is extremely low in levels I and IIB nodes, these regions do not need routine dissection, unless there is obvious metastatic disease [65]. Level VII should be removed and blocked with level VI nodes, in patients with obvious metastatic disease at level VI.

Berry picking

This is a procedure used mainly in the 60s and 70s and in which only suspicious and/or enlarged lymph nodes are removed. This type of surgery cannot achieve complete removal of metastatic disease and more lymph node will be found harboring metastatic thyroid carcinoma; as a consequence, there was a high incidence of recurrent disease in the neck requiring further surgery [77].

Nowadays, selective neck dissection (a compartment-oriented procedure) is the preferred type of surgery, which avoids the increased morbidity of the more extensive dissections, while at the same time minimizes local recurrence rates by removing overt or occult metastases that would be missed by the berry picking procedure [57,77].

Surgical strategy

There are two different surgical approaches in the management of PTC specifically regarding the role of CLND. Worldwide, the vast majority of surgeons (mainly in

Western countries) perform *selective (elective or therapeutic) CLND* (i.e., CLND in the presence of cervical lymphadenopathy). However, other surgeons (mainly from East countries, such as Japan) support *routine CLND*. As above noted, despite that CLND appears to have no impact on survival of the patients, its omission may be associated with increased loco-regional recurrence rates, which may have a negative impact mainly on patient's quality-of-life but also (to a less extent and in some subgroups of patients) on overall survival. These considerations have refueled the discussion about the optimal management of cervical lymph nodes in the management of PTC (i.e., selective vs. routine CLND) and have led to a shift towards a more aggressive approach in investigating and sampling of the regional lymph nodes, in the hope that more aggressive initial surgery in patients with cervical lymph node metastases will decrease loco-regional recurrence rates [78].

Elective vs. routine CLND

Elective or therapeutic CLND

Elective or therapeutic CLND involves the removal of regional lymph nodes that are found abnormal either preoperatively (clinically and/or radiographically) or intraoperatively and therefore proven or suspected to harbor metastatic disease. Performance of a therapeutic CLND is based on the fact that regional disease control is necessary to prevent morbidity from local tumor growth, to maintain quality-of-life, and to maximize disease-free and possibly overall survival [79]. This concept is well-accepted in the treatment of PTC. As above noted, compartment-oriented lymph node dissections are recommended in all the guidelines for patients who have known lymph node metastases. These dissections should be preferred over 'berry picking' [77,78]. Radical neck dissection is rarely indicated. This approach decreases the risk of recurrence in low-risk patients and may prolong survival in high-risk patients. Proponents of elective CLND emphasize that metastases in nonpalpable lymph nodes will remain indolent and rarely become clinically significant, in argument against routine CLND (see above) [15,74].

Routine or prophylactic CLND

Routine or prophylactic CLND is the removal of lymph nodes that are normal on physical examination and radiographic imaging. This approach is based on the theory that early detection and removal of microscopic disease in regional lymph nodes may prevent recurrence/metastatic spread and improve disease-free and possibly overall survival [57]. Proponents of this strategy emphasize the relatively high frequency of lymph node metastases mainly in central and lateral lymph nodes (see above) [73]. They also note that recurrence—especially in the central compartment—may be very difficult to treat surgically [5,80]. Central CLND can be performed without extension of the surgical incision. Routine CLND allows accurate staging of the disease, which is important to assess the risk of recurrence and to determine the need for adjuvant postoperative radioiodine therapy. However, in contrast to elective (therapeutic)

CLND, the role of routine (prophylactic) CLND in the management of PTC remains highly controversial. The argument against routine CLND for PTC includes two main concepts: first, that lymphatic metastases have not been shown to increase overall survival, and second, that more radical surgery is associated with increased complication rates [58]. However, the possible benefits of prophylactic CLND should be weighed against the potential risks [81]. Opponents of routine CLND emphasize that reoperation for recurrent disease can be performed with acceptable morbidity by experienced surgeons; this argues against routine CLND for PTC. Routine CLND is championed mainly in Japan, where the use of radioactive is strictly limited by law and it is considered that the effectiveness of radioiodine ablation of cervical lymph nodes is limited [45,53,71,82]. Some Japanese authors have concluded that routine modified radical neck dissection improves not only local recurrence rates, but also the cause-specific survival in some group of patients (i.e., female patients older than 60 years of age, patients whose primary tumor had extrathyroidal invasion) [53]. Others recommend prophylactic CLND for patients having two or more of the four following clinicopathological characteristics: male gender, age > 55 years, maximal tumor diameter >3 cm, and massive extrathyroid extension [42]. According to the authors, these patients are at high risk for lymph node recurrence, even after prophylactic CLND.

Practical considerations

Preoperative investigation/documentation

Because of the high prevalence of metastatic cervical lymph node involvement in PTC, careful high-quality ultrasound (US) examination of the neck by an experienced radiologist should be performed preoperatively in all patients to properly plan surgical intervention [4,83,84]. Preoperative US will identify suspicious cervical lymphadenopathy in 20–30% of cases; obviously, this finding will result in an alteration of the planned surgical approach [85,86]. On the other hand, preoperative US should not lead to an overly aggressive surgical approach to small lateral neck lymph nodes that may be of little clinical consequence and are likely to be easily treated with subsequent radioactive iodine remnant ablation (see below). Preoperative assessment of vocal cord function should be a mandatory part of the work-up of any patient who has thyroid cancer [83]. This will allow adequate documentation of any possible infiltration of the recurrent laryngeal nerve by the tumor, a finding which may have significant medicolegal importance postoperatively.

Incision and access

Most commonly, total thyroidectomy and CLND are performed through a transverse (horizontal) or curvilinear incision in the suprasternal area at the level of the cricoid cartilage, with a J-shaped or a hockey stick incision along the border of the sternocleidomastoid muscle, up to the mastoid process, if indicated. A McFee incision (double transverse incision) should be avoided because of poor

esthetic results, but may occasionally be necessary when higher lymph nodes are palpable and are not accessible through the typical incision [87]. Access to the central compartment is possible through the usual incision of thyroidectomy (i.e., without extension). The inferior part of the central compartment is less easily accessible and requires experience and adequate training on the part of the operating surgeon. Access to the lateral compartment may be more difficult and usually require extension of the incision [42].

Management of parathyroids

During level VI lymph node dissection (central CLND) at least the superior parathyroid glands should be preserved in situ. It is usually difficult to perform an adequate paratracheal node dissection and preserve the inferior parathyroid glands in situ. Therefore, the inferior parathyroid glands are usually harvested from the surgical specimen and autografted into the sternocleidomastoid (or strap) muscle(s) to prevent permanent hypoparathyroidism [57].

Extent of CLND

Currently, therapeutic CLND is performed on a compartment-oriented basis. In patients with suspicious or clearly abnormal clinical or US findings in the central and/or lateral neck, this compartment-oriented operation includes a central and/or lateral CLND [83]. Central CLND removes all lymph nodes immediately adjacent to the thyroid, especially in the tracheoesophageal groove and proceeds laterally to and includes the lymph nodes within the carotid sheath [87]. Lateral CLND involves removal of all lymph nodes and soft tissues in levels IIA (most commonly level IIB nodes are not involved), III, IV and V, usually with preservation of the internal jugular vein, carotid artery, vagus nerve, phrenic nerve, sternocleidomastoid muscle, and spinal accessory nerve [57,65,83,88]. As the detection of lateral neck disease becomes more sensitive, patients may be found to have limited disease (for example, a single abnormal lymph node) in level IV or VB. In such cases, it may be reasonable to limit the dissection to the lower neck (levels IV and VB).

The optimal extent of prophylactic CLND is not clear. The British Thyroid Association (BTA) and American Thyroid Association (ATA) (2006 task force disclosure on thyroid cancer) [4] argue that the potential increased morbidity is small in experienced hands, and therefore a strong argument can be made that central-neck lymph nodes should be routinely dissected in all patients with known PTC and no known preoperative or intraoperative adenopathy [57,87]. The ATA recommends this tactic (i.e., routine central CLND) for patients with PTC and Hurthle cell cancer [4]. Routine central CLND is also supported by other international guidelines [90]. The European Thyroid Association (ETA) notes that routine central CLND may also provide useful and accurate pathologic N staging information that may guide subsequent treatment and follow-up [84]. This approach may enhance the effect of radioiodine ablation therapy by removing potentially positive nodes, may prevent central-neck recurrence, and may improve survival compared with historical controls [5,57]. Of note, it has

been reported that total thyroidectomy performed in conjunction with ipsilateral CLND in patients with PTC and no apparent lymphadenopathy results in significantly lower serum thyroglobulin levels, thereby facilitating postoperative follow-up [91]. This strategy, however, remains controversial. Other guidelines (for example, AACE/AES [American Association of Clinical Endocrinologists/American Association of Endocrine Surgeons] and NCCN [National Comprehensive Cancer Network] guidelines) do not recommend routine central CLND, particularly in low-risk patients [84,92,93]. Clearly, this extensive surgery is not recommended for surgeons who have not had the necessary experience in thyroid surgery and central-neck anatomy. Patients without a cytologic diagnosis of PTC before surgery (e.g., indeterminate thyroid nodule on FNA) and no evidence of adenopathy should not undergo any form of lymphadenectomy unless grossly abnormal paratracheal lymph nodes are seen at the time of operation. Other groups recommend removal of levels II–IV lymph nodes in routine CLND. To reduce postoperative morbidity (mainly postoperative hypocalcemia), Son et al. have proposed limited central CLND in node-negative patients [94]. The location of the lymph nodes may also be useful for the decision-making. Prophylactic lateral neck dissection for patients with PTC is generally not recommended [79]. The surgeon should remember that the incidence of malignant lymph nodes is much higher in levels III, IV, and VI than in level II [60]. Level V metastases are not uncommon, with level VB nodes being more commonly involved than level VA nodes [42]. When any of the levels II, III or IV have nodal disease, there is a significant association with positivity in level V [6,7,88]. Factors suggestive level V disease include multifocal thyroid tumor, metastatic disease in level II, III or IV, contralateral metastasis, or perineural/lymphovascular invasion [88,95]. However, in the process of surgical decision-making, the surgeon should remember that dissection of level V nodes carries a high morbidity. Possible benefits should always be weighted against potential morbidity; moreover, it should be remembered that the biological significance of occult level V metastases in the non-operated neck remains unknown, particularly when patients are treated with radioactive iodine ablation and suppressive doses of exogenous thyroid hormone [88].

In the discussion about the extent of prophylactic CLND in PTC, it should be remembered that the impact of the central compartment recurrence differs from that of a lateral compartment. Reoperation for recurrence in the lateral compartment can be performed more easily than that for recurrence in the central compartment, where more critical structures (i.e., trachea, great vessels, etc) are located. Therefore, since metastases in the central compartment are very common and given that surgery for recurrence in the central compartment may be a complicated procedure, prophylactic central CLND during the initial thyroid surgery (usually through the same incision) seems to be a reasonable management option [5,44,54,55,80].

The role of contralateral neck dissection

Although at the time of surgery localization of metastatic lateral lymph nodes is usually *ipsilateral* to the primary

tumor, about 20–25% of patients with unilateral PTC will have involvement of the *contralateral* lateral neck compartment [60,70,72]. The risk of contralateral lateral compartment lymph node involvement increases with increasing burden of ipsilateral lymph node involvement [72]. Bilateral CLND is generally not recommended [15,24,69]. However, the presence of bilateral or contralateral neck disease is indicative of aggressive biological behavior and complete dissection of the contralateral neck nodes may be warranted.

What's the role of CLND in microscopic metastatic spread?

Given the relatively benign biological behavior of lymph node micrometastases and the availability (at least in most western countries) of radioactive iodine ablation, most surgeons would not select an aggressive surgical approach. Such a conservative approach is favored for patients with PTMC [42,96]. However, in selected patients with PTMC (i.e., with known [clinically or ultrasonographically] cervical lymphadenopathy, multifocal disease, extrathyroid extension, especially when PTMC is >5mm) a more aggressive therapeutic strategy may be indicated [16,19,20]. In these cases, usually a central CLND is performed on the ipsilateral side, ideally at the time of thyroidectomy [96,97]. Central lymph node metastases of PTMC may be detected by using the sentinel lymph node biopsy (see below).

Complications

Despite that –in experienced hands– CLND can be performed safely, it may be associated with a potentially significant morbidity [76,98] (Table 2). Ito et al. [42] have reported that the incidence of major complications was 24% following total/near-total thyroidectomy with modified CLND. The complication rate increases as the cervical LND range becomes more radical [99–102]. Therefore, decreasing the extent of CLND would reduce postoperative side effects. The fear of postoperative complications

Table 2 Complications following cervical lymph node dissection for thyroid cancer.

Central-neck dissection
Hypoparathyroidism (temporary/permanent)
Recurrent (inferior) laryngeal nerve injury
Superior laryngeal nerve injury
Hemorrhage/seroma
Lateral neck dissection
Hypoparathyroidism (temporary/permanent)
Hemorrhage/seroma
Chyle leak
Wound infection
Nerve injuries (accessory, ramus mandibularis, sympathetic [Horner's syndrome], phrenic, brachial plexus, cutaneous cervical plexus)

From Ref. # [79], modified.

should not jeopardize the appropriateness of surgical therapy and proper oncologic outcome, however. Reoperation for recurrence (especially to the central lymph nodes) due to inadequate initial surgery may be much more technically demanding and associated with increased morbidity [103].

Hypoparathyroidism

Transient hypoparathyroidism is a very frequent complication following central CLND, more commonly following bilateral CLND [55]. To prevent permanent hypoparathyroidism, autotransplantation (in the sternocleidomastoid muscle or in the strap muscles) should be liberally performed if—at the time of surgery—any parathyroid gland is identified to be devascularized.

Recurrent laryngeal nerve injury

Total thyroidectomy and CLND include considerable dissection in the paratracheal area, especially along the course of the recurrent laryngeal nerve (RLN). Therefore, RLN injury may occur. This complication can be avoided if the RLN is identified and protected during surgery. Bilateral RLN palsy is a severe complication, but fortunately quite rare. Patients undergoing bilateral modified neck dissection should be observed very closely for this complication. If there is any concern about the patency of the airway in the recovery room, the patient should be monitored closely, evaluated with fiber-optic laryngoscopy, and re-intubated (if indicated). True bilateral vocal cord paralysis may require tracheostomy to secure the airway.

Thoracic duct injury

This complication can be observed following level IV CLND and is due to injury of the thoracic duct near its end (at the junction of the left jugular and subclavian vein). Thoracic duct injury is manifested by chyle leak. If chyle leak is identified at the time of surgery, it should be managed by suture-ligation (which may include muscle buttress from the sternocleidomastoid) [76]. Sometimes, chyle leak may be manifested postoperatively as large amount of chylous fluid into the drainage system. In these cases, a conservative approach with observation, pressure dressings, a fat-free (medium-chain triglyceride) diet or potentially total parenteral nutrition is successful in most (~90 %) patients. However, in a small percentage of patients chyle leak may persist. In these cases surgical exploration should be considered; at surgery, the surgeon should identify and secure by suture-ligation any chyle leak [56]. Occasionally, this may be difficult, because of the extensive local inflammation, which may cause further laceration of soft tissue during suture placement. The use of a biological sealant should be considered under these circumstances. In some cases, a chyloma may be observed, which can be treated easily by percutaneous aspiration (sometimes multiple). Injection of tetracycline or other sclerosing agents has been proposed by some authors, but may lead to considerable scarring and fibrosis, inflammatory reaction, and pain [76].

Neck anesthesia/neuropathic pain/decreased shoulder mobility

Transection of the cervical rootlets and/or manipulations/injury of the spinal accessory nerve during CLND may lead to neck sensory abnormality (anesthesia, numbness, and/or neuropathic pain), edema and limitation of neck/shoulder movement, decline in speech and eating abilities, etc [99–101,104]. These complications usually are observed following lateral (level V) CLND and may have a significant impact on patient's quality-of-life (QOL), altering daily activities, social function, and professional performance [102,104–106]. Spinal accessory nerve should be preserved whenever possible (if disease is not encircling the nerve, a very rare occurrence) to reduce the incidence of these complications [65]; however, varying degrees of dysfunction of the spinal accessory nerve are common after level V dissection even with nerve preservation. Indeed, even after complete nerve preservation, shoulder pain has been observed in 79% of patients after radical neck dissection, 65% of patients after modified radical neck dissection and 52% of patients after selective neck dissection [99,100]. This is due to neuroapraxia, caused by excessive traction, extensive dissection and skeletonization, devascularization and ischemia, thermal injury, blunt trauma during dissection, leading to degeneration of the upper trapezius and sternocleidomastoid muscles [100,107]. These alterations have been documented by electromyography studies, which have confirmed increased latency and decreased amplitude in the operated neck. Often, shoulder function can improve with intensive physiotherapy.

Other complications

Injury of the ramus mandibularis (resulting in lip weakness) may occur during level I node dissection (level I is very rarely involved by PTC, however [see above]). Seroma is a relatively common complication after total thyroidectomy and neck dissection, and can invariably be treated conservatively, by observation (most seromas will resolve in a few days) or aspiration (sometimes multiple). Wound infection is quite rare [98]. If the wound is edematous or fluctuant, aspiration or opening of the wound may be required. Horner's syndrome (due to injury of the sympathetic chain, which lies deep to the carotid sheath and just anterior to the prevertebral fascia) and injury of the brachial plexus or hypoglossal nerve are quite rare [98]. Bleeding/hematoma are complications which can be prevented by meticulous hemostasis (Table 2).

Newer surgical approaches

Video-assisted technique

Recently, this technique has been proposed by some authors, especially for young women concerned with cosmetic outcome [108,109]. By using the video-assisted technique, the extended collar incision is avoided. However, this method has not been adequately validated in terms of oncologic safety and outcome, and experience

remains very limited in a few centers; currently, this method is considered as experimental.

Sentinel lymph node dissection

The concept of sentinel lymph node biopsy (SLNB) has become very popular during the last 15 years mainly for melanoma and breast cancer [110,111]. Sentinel lymph node is defined as the first lymph node draining a regional lymphatic basin from a primary tumor. Some authors have recently tried to investigate the potential role of SLNB in the management of patients with PTC. The SLNB philosophy is theoretically appealing for PTC, since it could detect subclinical lymph node metastases, thereby allowing the formal CLND to be performed only in patients with documented lymph node metastases, thus avoiding the morbidity of CLND in a significant percentage of patients with node-negative disease. In other words, SLNB may be helpful in selecting patients who would benefit from CLND, thus reducing unnecessary surgery and possible morbidity in other patients [112,113]. This is a particularly important consideration, since surgical exploration and intraoperative palpation are inaccurate for predicting lymph node spread, particularly when metastatic lymph nodes are small (occult metastases, micrometastases), and when they are located in the central-neck compartment or behind the vessels. When positive, SLNB can guide compartment-oriented neck dissection. In patients with PTC, the sentinel node more commonly occurs within the central compartment [25]. Reported rates for central compartment sentinel nodes range between 75% and 85% [10,11]. Injection of isosulfan blue or methylene blue into the thyroid nodule has resulted in a high rate (>90%) of SLN identification [10,11,14]. Some authors have reported a high sensitivity (71–100%), a specificity of 100%, and a diagnostic accuracy ranging from 75% to 100% for predicting disease status in the remaining regional lymph node basin [9–14,112]. Diagnostic sensitivity may improve by using an intraoperative immunohistochemical stain for cytokeratin-7 [12]. False-negative results have been reported in up to 11% of patients in series where neck dissection follows the SLNB; this remains a serious concern regarding the value of SLNB [10,11]. The extensive lymphatic network in the neck may complicate the practical application of the theoretical concept of SLNB in patients with thyroid cancer. Up to the present time, experience remains relatively limited and most endocrine surgeons remain skeptical about the appropriateness of such an approach in the management of PTC. Additional studies are needed which should include larger number of patients and a long follow-up.

Postoperative management

TSH suppression

Given that PTC is a TSH-dependent tumor, suppression of TSH with supraphysiologic doses of levothyroxine to decrease the rate of progression and recurrence of thyroid cancer has been a cornerstone of treatment for more than 40 years; many retrospective and prospective studies have shown the benefits of TSH suppression regarding disease

recurrence, progression, and mortality [39,114–116]. In contrast, rapid tumor recurrence has been reported after withdrawal of thyroid hormone or administration of recombinant TSH [117].

The precise level of TSH suppression required has not been adequately defined, especially for the low-risk patients. After adequate treatment (surgery, with or without radioiodine therapy) thyroid hormone replacement should be administered at sufficient doses to prevent symptomatic hypothyroidism and to induce a subclinical hyperthyroid state (i.e., a suppressed TSH value with normal T4 and T3 levels and without signs or symptoms of thyrotoxicosis). Largely because the risk for atrial fibrillation and osteoporosis in older patients seems to rise when the TSH falls below 0.1 mU/L, the ATA and American College of Clinical Endocrinology (ACCE) recommend a goal TSH of 0.1–0.4 mU/L for all patients except for high-risk patients who have a goal TSH of less than 0.1 mU/L [4,92]. The National Comprehensive Cancer Network (NCCN) does not give specific target goals, but notes that low-risk patients should be titrated to achieve a TSH just below the lower bound of the reference range [93]. The ETA and the BTA recommend suppression of TSH to less than 0.1 mU/L in all patients, but the ETA notes that after 3–5 years of disease-free survival, the TSH suppression may be lessened even in high-risk patients. Similarly, low-risk patients who have had several years of disease-free survival can be titrated to a TSH between 0.5 and 1 mU/L [84,89]. From a practical point of view, a reasonable practice is to start a 2 µg/kg/day dose, and titrate replacement therapy accordingly, based on follow-up thyroid function tests obtained 6–8 weeks later [57]. Based on the results of retrospective studies, it is known that the replacement dose for the average patient with PTC is 2.11 µg/kg/day and the dose required to achieve a suppressed TSH ranges from 2.5 to 2.9 µg/kg/day [118]. Higher doses on a per-kilogram basis are required for children and adolescents, as well as pregnant women [57]. In the patient who has been hypothyroid for a short time (typically the case in patients with PTC who are rendered hypothyroid), one can usually start at the full replacement dose without concern for causing significant side effects.

The length of suppression therapy remains controversial and should be individualized. For the low-risk patients (representing the vast majority of patients) who remain without evidence of recurrence after 5 years, a reasonable strategy is to allow the TSH to rise to the low normal range. This strategy has also been suggested for low-risk patients who remain disease-free after 1 year following initial therapy. In contrast, patients with known or suspected residual disease and no relative contraindications should continue TSH suppression indefinitely [57].

Chronic TSH suppression may be associated with some morbidity, such as bone loss (particularly in postmenopausal women), cardiac effects (mainly atrial fibrillation, particularly in older patients), etc [119,120]. Moreover, a negative effect on mortality has been described [121]. The risk of adverse effects is greatest in those whose TSH is maintained below 0.1 mU/L [122]. Therefore, the potential benefits of long-term TSH suppression should always be weighed against the potential risks of subclinical hyperthyroidism. These considerations

should always be taken into account when deciding how aggressive the TSH suppression should be and for how long it should be offered to the patient.

Radioactive iodine therapy (RIT)

Radioactive iodine for the treatment of differentiated thyroid cancer became established in the 1960s when it was demonstrated that metastatic disease could be destroyed with a subsequent increase in survival for those with metastatic disease [123]. Its use increased in the 1970s and evidence from this period supported the role of RIT in dealing with microscopic deposits of thyroid cancer [30,124]. Currently, RIT may be indicated either as an alternative of CLND (following near total or total thyroidectomy) or as adjuvant therapy (after near total or total thyroidectomy *and* CLND) for PTC [4,57]. The first use of RIT is widely practiced in most western countries. RIT is recommended for patients at high risk for recurrence/death from the disease, as classified by the usual clinico-pathologic staging systems. In these patients, RIT reduced the risk of local and distal metastases [125], as well as mortality [39]. In contrast, the role of RIT is limited in low-risk patients. A review of more than 2500 patients at the Mayo Clinic showed no decrease in mortality or local recurrence in patients with low-risk disease (MACIS <6) [126]. From a surgical point of view, it should be noted that complete removal of the normal and pathologic thyroid parenchyma increases the efficiency of adjuvant RIT in destroying any metastatic/micrometastatic disease that may be present. RIT is much less effective in ablating palpable regional metastatic lymph node involvement.

Conflict of interest statement

None declared.

Authorship

Guarantor of the integrity of the study: G. Sakorafas

Study concepts: G. Sakorafas

Study design: G. Sakorafas

Definition of intellectual content: G. Sakorafas

Literature research: D. Sampanis

Clinical studies: D. Sampanis

Experimental studies: D. Sampanis

Data acquisition: D. Sampanis

Data analysis: G. Sakorafas

Manuscript preparation: G. Sakorafas

Manuscript editing: M. Safioleas, G. Sakorafas

Manuscript review: M. Safioleas, G. Sakorafas

References

- [1] Gosnell JE, Clark OH. Surgical approaches to thyroid tumors. *Endocrinol Metab Clin North Am* 2008;37:437–55.
- [2] Hundahl SA, Cady B, Cunningham MP, et al. Initial results from a prospective cohort study of 5583 cases of thyroid carcinoma treated in the United States during 1996. U.S. and German Thyroid Cancer Study Group. *Cancer* 2000;89:202–17.
- [3] Jemal A, Siegel R, Ward E, Murray T, Xu J, Thun Mj. Cancer statistics. *CA Cancer J Clin* 2007;57:43–66.
- [4] Cooper DS, Doherty GM, Haugen BR, Kloos RT, Lee SL, Mandel SJ, et al. Management guidelines for patients with thyroid nodules and differentiated thyroid cancer. *Thyroid* 2006;16:109–42.
- [5] Tisell LE, Nilsson B, Molne J, Hansson G, Fjalling M, Jansson S, et al. Improved survival of patients with papillary thyroid cancer after surgical microdissection. *World J Surg* 1996;20:854–9.
- [6] Kupferman ME, Patterson M, Mandel SJ, LiVolsi V, Weber RS. Patterns of lateral neck metastasis in papillary thyroid carcinoma. *Arch Otolaryngol Head Neck Surg* 2004;130:857–60.
- [7] Sivanandan R, Soo KC. Pattern of cervical lymph node metastases from papillary carcinoma of the thyroid. *Br J Surg* 2001;88:1241–4.
- [8] Shaha AR, Shah JP, Loree TR. Patterns of nodal and distant metastasis based on histologic varieties in differentiated carcinoma of the thyroid. *Am J Surg* 1996;172:692–4.
- [9] Kelemen PR, Van Herle AJ, Giuliano AE. Sentinel lymphadenectomy in thyroid malignant neoplasms. *Arch Surg* 1998;133:288–92.
- [10] Dixon E, McKinnon JG, Pasiaka JL. Feasibility of sentinel lymph node biopsy and lymphatic mapping in nodular thyroid neoplasms. *World J Surg* 2000;24:1396–401.
- [11] Fukui Y, Yamakawa T, Taniki T, Numoto S, Miki H, Monden Y. Sentinel lymph node biopsy in patients with papillary thyroid carcinoma. *Cancer* 2001;92:2868–74.
- [12] Arch-Ferrer J, Velazquez D, Fajardo R, Gamboa-Dominguez A, Herrera MF. Accuracy of sentinel lymph node in papillary thyroid carcinoma. *Surgery* 2001;130:907–13.
- [13] Pelizzo MR, Boschin IM, Toniato A, Bernante P, Piotto A, Rinaldo A, et al. The sentinel node procedure with Patent Blue V dye in the surgical treatment of papillary thyroid carcinoma. *Acta Otolaryngol* 2001;121:421–4.
- [14] Dzodic R, Markovic I, Inic M, Jokic N, Djuricic I, Zegarac M, et al. Sentinel lymph node biopsy may be used to support the decision to perform modified radical neck dissection in differentiated thyroid carcinoma. *World J Surg* 2006;30:841–6.
- [15] Wada N, Duh QY, Sugino K, Iwasaki H, Kameyama K, Mimura T, et al. Lymph node metastasis from 259 papillary thyroid microcarcinomas: frequency, pattern of occurrence and recurrence, and optimal strategy for neck dissection. *Ann Surg* 2003;237:399–407.
- [16] Sakorafas GH, Giotakis J, Stafyla V. Papillary thyroid microcarcinoma: a surgical perspective. *Cancer Treat Rev* 2005;31:423–38.
- [17] Hubert Jr JP, Kiernam PD, Beahrs OH. Occult papillary carcinoma of the thyroid. *Arch Surg* 1980;115:394–6.
- [18] Grant CS, van Heerden JA. Papillary thyroid microcarcinoma: a study of 535 cases observed in a 50-year period. *Surgery* 1992;112:1139–45.
- [19] Chow SM, Lay SC, Chan JK, Au SK, Yau S, Lau WH. Papillary microcarcinoma of the thyroid—prognostic significance of lymph node metastasis and multifocality. *Cancer* 2003;98:31–40.
- [20] Ito Y, Tomoda C, Urano T, Takamura Y, Miya A, Kobayashi K, et al. Clinical significance of metastasis to the central compartment from papillary microcarcinoma of the thyroid. *World J Surg* 2006;30:91–9.
- [21] Gulben K, Berberoglu U, Celen O, Mersin HH. Incidental papillary microcarcinoma of the thyroid-factors affecting lymph node metastasis. *Langenbecks Arch Surg* 2008;393:25–9.
- [22] Lee SH, Lee SS, Jin SM, Kim JH, Rho YS. Predictive factors for central compartment lymph node metastasis in thyroid papillary microcarcinoma. *Laryngoscope* 2008;118:659–62.

- [23] Seigel RJ. Surgical pathology of lymph nodes in cancer staging: routine and specialized techniques. *Surg Oncol Clin N Am* 1996;5(1):25–31.
- [24] Qubain SW, Nakano S, Baba M, Takao S, Aikou T. Distribution of lymph node micrometastasis in pN0 well-differentiated thyroid carcinoma. *Surgery* 2002;131:249–56.
- [25] Cranshaw IM, Carnaille B. Micrometastases in thyroid cancer. An important finding? *Surg Oncol* 2008;17:253–8.
- [26] Cranshaw IM, Jany T, Arnalsteen L, Pattou F, Carnaille B. Significance of lymph node micrometastases in papillary thyroid carcinoma. *ANZ J Surg* 2007;77(Suppl. 1):A21.
- [27] Shaha AR, Shah J, Loree TR. Patterns of failure in differentiated carcinoma of the thyroid based on risk groups. *Head Neck* 1998;20:26–30.
- [28] Grebe SK, Hay ID. Thyroid cancer nodal metastases: biologic significance and therapeutic considerations. *Surg Oncol Clin N Am* 1996;5:43–63.
- [29] Harwood J, Clark OH, Dunphy JE. Significance of lymph node metastasis in differentiated thyroid cancer. *Am J Surg* 1978;136:107–12.
- [30] Mazzaferri EL, Young RL. Papillary thyroid carcinoma: a 10 year follow-up report of the impact of therapy in 576 patients. *Am J Med* 1981;70:511–8.
- [31] McHenry CR, Rosen IB, Walfish PG. Prospective management of nodal metastases in differentiated thyroid cancer. *Am J Surg* 1991;162:353–6.
- [32] McCohaney WM, Hay ID, Woolner LB, van Heerden JA, Taylor WF. Papillary thyroid cancer treated at the Mayo Clinic, 1946 through 1970: initial manifestations, pathologic finding, therapy, and outcome. *Mayo Clin Proc* 1986;61:978–96.
- [33] Mazzaferri EL. Papillary thyroid carcinoma: factors influencing prognosis and current therapy. *Semin Oncol* 1987;14:315–32.
- [34] Akslen LA. Prognostic importance of histologic grading in papillary thyroid carcinoma. *Cancer* 1993;72:2680–5.
- [35] Wada N, Suganuma N, Nakayama H, Masudo K, Rino Y, Masuda M, et al. Microscopic regional lymph node status in papillary thyroid carcinoma with and without lymphadenopathy and its relation to outcomes. *Langenbecks Arch Surg* 2007;392:417–22.
- [36] Hughes CJ, Shaha AR, Shah JP, Loree TR. Impact of lymph node metastasis in differentiated carcinoma of the thyroid: a matched-pair analysis. *Head Neck* 1996;18:127–32.
- [37] Sugino K, Kure Y, Iwasaki H, Ozaki O, Mimura T, Matsumoto A, et al. Metastases to the regional lymph nodes, lymph node recurrence, and distant metastases in nonadvanced papillary thyroid carcinoma. *Surg Today* 1995;25:324–8.
- [38] Cady B, Rossi R. An expanded view of the risk-group definition in differentiated thyroid carcinoma. *Surgery* 1988;104:947–53.
- [39] Mazzaferri EL, Jhiang SM. Long-term impact of initial surgical and medical therapy on papillary and follicular thyroid cancer. *Am J Med* 1994;97:418–28.
- [40] Hay ID, Bergstrath EJ, Goellner JR, Ebersold JR, Grant CS. Predicting outcome in papillary thyroid carcinoma: development of a reliable prognostic scoring system in a cohort of 1779 patients surgically treated at one institution during 1940 through 1989. *Surgery* 1993;114:1050–8.
- [41] Kukkonen ST, Haapiainen RK, Rrassila KO, Sivula AH. Papillary thyroid carcinoma: the new, age-related TNM classification system in a retrospective analysis of 199 patients. *World J Surg* 1990;14:837–42.
- [42] Ito Y, Higashiyama T, Takamura T, Miya A, Kobayashi K, Matsuzuka F, et al. Risk factors for recurrence to the lymph node in papillary thyroid carcinoma patients without preoperatively detectable lateral node metastasis: validity of prophylactic modified radical neck dissection. *World J Surg* 2007;31:2085–91.
- [43] Lundgren CI, Hall P, Dickman PW, Zedenius J. Clinically significant prognostic factors for differentiated thyroid carcinoma: a population-based, nested case-control study. *Cancer* 2006;106:524–31.
- [44] Scheumann GF, Gimm O, Wegener G, Hundeshagen H, Dralle H. Prognostic significance and surgical management of locoregional lymph node metastases in papillary thyroid cancer. *World J Surg* 1994;18:559–68.
- [45] Ohshima A, Yamashita H, Noguchi S, Uchino S, Watanabe S, Toda M, et al. Indications for bilateral modified radical neck dissection in patients with papillary carcinoma of the thyroid. *Arch Surg* 2000;135:1194–9.
- [46] Yamashita H, Noguchi S, Murakami N, Kawamoto H, Watanabe S. Extracapsular invasion of lymph node metastasis is an indicator of distant metastasis and poor prognosis in patients with thyroid papillary carcinoma. *Cancer* 1997;80(12):2268–72.
- [47] Rossi RL, Cady B, Silverman ML, Wool MS, Horner TA. Current trends of conservative surgery for differentiated thyroid carcinoma. *World J Surg* 1986;10:612–22.
- [48] DeGroot LJ, Kaplan EL, McCormick M, Straus FH. Natural history, treatment, and course of papillary thyroid carcinoma. *J Clin Endocrinol Metab* 1990;71:414–24.
- [49] Byar DP, Green SB, Dor P, Williams ED, Colon J, van Gilse HA, et al. A prognostic index for thyroid carcinoma: a study of the E.O.R.T.C. thyroid cancer cooperative group. *Eur J Cancer* 1979;15:1033–41.
- [50] Bhattacharyya N. Surgical treatment of cervical nodal metastases in patients with papillary thyroid carcinoma. *Arch Otolaryngol Head Neck Surg* 2003;129:1101–4.
- [51] Bhattacharyya N. A population-based analysis of survival factors in differentiated and medullary thyroid carcinoma. *Otolaryngol Head Neck Surg* 2003;128:115–23.
- [52] Sugitani I, Kasai N, Fujimoto Y, Yanagisawa A. A novel classification system for patients with PTC: addition of the new variables of large (3 cm or greater) nodal metastases and reclassification during the follow-up period. *Surgery* 2004;135:139–48.
- [53] Noguchi S, Murakami N, Yamashita H, Toda M, Kawamoto H. Papillary thyroid carcinoma: modified radical neck dissection improves prognosis. *Arch Surg* 1998;133:276–81.
- [54] Simon D, Goretzki PE, Witte J, Roher HD. Incidence of regional recurrence guiding radicality in differentiated thyroid carcinoma. *World J Surg* 1996;20:860–6.
- [55] Lee YS, Kim SW, Kim SW, et al. Extent of routine central lymph node dissection with small papillary thyroid carcinoma. *World J Surg* 2007;31:1954–9.
- [56] Esnaola NF, Cantor SB, Sherman SI, Lee JE, Evans DB. Optimal treatment strategy in patients with papillary thyroid cancer: a decision analysis. *Surgery* 2001;130:921–30.
- [57] Grubbs EG, Rich TA, Li G, Sturgis EM, Younes MN, Myers JN, et al. Recent advances in thyroid cancer. *Curr Probl Surg* 2008;45:156–250.
- [58] Grodski S, Cornford L, Sywak M, Sidhu S, Delbridge L. Routine level VI lymph node dissection for papillary thyroid cancer: surgical technique. *ANZ J Surg* 2007;77:203–8.
- [59] Ying M, Ahuja A. Sonography of neck lymph nodes. Part I: normal lymph nodes. *Clin Radiol* 2003;58:351–8.
- [60] Fish SA, Langer JE, Mandel SJ. Sonographic imaging of thyroid nodules and cervical lymph nodes. *Endocrinol Metab Clin North Am* 2008;37:401–17.
- [61] Som PM, Curtin HD, Mancuso AA. An imaging-based classification for the cervical nodes designed as an adjunct to recent clinically based nodal classifications. *Arch Otolaryngol Head Neck Surg* 1999;125:388–96.
- [62] Robbins KT, Clayman G, Levine PA, Medina J, Sessions R, Shaha A, et al. Neck dissection classification update: revisions proposed by the American Head and Neck Society and the American Academy of Otolaryngology – Head and Neck Surgery. *Arch Otolaryngol Head Neck Surg* 2002;128:751–8.

- [63] Shaha AR. Management of the neck in thyroid cancer. *Otolaryngol Clin North Am* 1998;31:823–31.
- [64] Roh JL, Kim JM, Park CI. Lateral cervical lymph node metastases from papillary thyroid carcinoma: pattern of nodal metastases and optimal strategy for neck dissection. *Ann Surg Oncol* 2008;15:1177–82.
- [65] Lee J, Sung TY, Nam KH, Chung WY, Park CS. Is level IIb lymph node dissection always necessary in N1b papillary thyroid carcinoma patients? *World J Surg* 2008;32:716–21.
- [66] Shah JP. Cervical lymph node metastases—diagnostic, therapeutic and prognostic implications. *Oncology* 1990;4: 61–9.
- [67] Caron NR, Tan YY, Ogiwie JB, Triponez F, Reiff ES, Kebebew E, et al. Selective modified radical neck dissection for papillary thyroid cancer—is level I, II and V dissection always necessary? *World J Surg* 2006;30:833–40.
- [68] Gimm O, Rath FW, Dralle H. Pattern of lymph node metastases in papillary thyroid carcinoma. *Br J Surg* 1998;85: 252–4.
- [69] Roh JL, Park JY, Park CI. Total thyroidectomy plus neck dissection in differentiated papillary thyroid carcinoma patients: pattern of nodal metastasis, morbidity, recurrence, and postoperative levels of serum parathyroid hormone. *Ann Surg* 2007;245:604–10.
- [70] Machens A, Hinze R, Thomusch O, Dralle H. Pattern of nodal metastasis for primary and reoperative thyroid cancer. *World J Surg* 2002;26:22–8.
- [71] Noguchi S, Noguchi A, Murakami N. Papillary carcinoma of the thyroid. I. Developing pattern of metastasis. *Cancer* 1970;26:1053–60.
- [72] Mirallie E, Visset J, Sagan C, Hamy A, Le Bodic MF, Paineau J. Localization of cervical node metastasis of papillary thyroid carcinoma. *World J Surg* 1999;23:970–4.
- [73] Machens A, Holzhausen HJ, Dralle H. Skip metastases in thyroid cancer leaping the central lymph node compartment. *Arch Surg* 2004;139:43–5.
- [74] Robbins KT, Atkinson J, Byers RM, Cohen JI, Lavertu P, Pellitteri P. The use and misuse of neck dissection for head and neck cancer. *J Am Coll Surg* 2001;193:91–102.
- [75] Byers RM. Neck dissection: concepts, controversies, and technique. *Semin Surg Oncol* 1991;7:9–13.
- [76] Shaha AR. Complications of neck dissection for thyroid cancer. *Ann Surg Oncol* 2008;15:397–9.
- [77] Musacchio MJ, Kim AW, Vijungco JD, Prinz RA. Greater local recurrence occurs with 'berry picking' than neck dissection in thyroid cancer. *Am Surg* 2003;69:191–6.
- [78] Palazzo FF, Gosnell J, Savio R, Reeve TS, Sidhu MS, et al. Lymphadenectomy for papillary thyroid cancer: changes in practice over four decades. *Eur J Surg Oncol* 2006;32:340–4.
- [79] Tuttle RM, Loboef R, Martorella AJ. Papillary thyroid cancer: monitoring and therapy. *Endocrinol Metab Clin North Am* 2007;36:753–78.
- [80] Noguchi M, Kumaki T, Taniya T, Miyazaki I. Bilateral cervical lymph node metastases in well differentiated thyroid cancer. *Arch Surg* 1990;125:804–6.
- [81] Henry JF, Gramatica L, Denizot A, Kvachenyuk A, Puccini M, Defechereux T. Morbidity of prophylactic lymph node dissection in the central neck area in patients with papillary thyroid carcinoma. *Langenbecks Arch Surg* 1998;383:167–9.
- [82] Noguchi M, Earashi M, Kitagawa H, Ohta N, Thomas M, Miyazaki I, et al. Papillary thyroid cancer and its surgical management. *J Surg Oncol* 1992;49:140–9.
- [83] Thyroid carcinoma. Available from: In: Clinical practice guidelines in oncology, vol 2007. National Comprehensive Cancer Network, Inc http://www.nccn.org/professionals/physician_gls/PRF/thyroid.pdf; 2007. Version 2.2007.
- [84] Pacini F, Schlumberger M, Dralle H, Ilisea R, Smith Y, Viersinga V. European consensus for the management of patients with differentiated thyroid carcinoma of the follicular epithelium. *Eur J Endocrinol* 2006;154:787–803.
- [85] Shimamoto K, Satake H, Sawaki A, Ishigaki T, Funahashi H, Imai T. Preoperative staging of thyroid papillary carcinoma with ultrasonography. *Eur J Radiol* 1998;29:4–10.
- [86] Solorzano CC, Carneiro DM, Ramirez M, Lee TM, Irvin GL. Surgeon-performed ultrasound in the management of thyroid malignancy. *Am Surg* 2004;70:576–82.
- [87] Kupferman ME, Weinstock YE, Santillan AA, Mishra A, Roberts D, Clayman GL, et al. Thyroid. In: Townsend: Sabiston textbook of Surgery. 18th ed. Philadelphia: Elsevier-Saunders; 2007. p. 707–45.
- [88] Kupferman ME, Weinstock EY, Santillan AA, et al. Predictors of level V metastasis in well-differentiated thyroid cancer. *Head Neck* 2008;30:1469–74.
- [89] BTA. British Thyroid Association and Royal College of Physicians: guidelines for the management of thyroid cancer in adults. Available at: www.british-thyroid-association.org; 2002.
- [90] Roher HD, Simon D, Goretzki PE. Guidelines in oncologic surgery – malignant thyroid tumours. *Lang Arch Chir Kongressbd* 1997;114:142–5.
- [91] Sywak M, Cornford L, Roach P, Stalberg P, Sidhu S, Delbridge L. Routine ipsilateral level VI lymphadenectomy reduces postoperative thyroglobulin levels in papillary thyroid cancer. *Surgery* 2006;140:1000–5.
- [92] Son YI, Jeong HS, Baek CH, Chung MK, Ryu J, Chung JH, et al. ThyroidCarcinomaTaskForce. AACE/AAES medical/surgical guidelines for clinical practice: management of thyroid carcinoma. American Association of Clinical Endocrinologists. American College of Endocrinology. *Endocr Pract* 2001; 7:202–20.
- [93] National Comprehensive Cancer Network. NCCN clinical practice guidelines in oncology. Thyroid carcinoma. Version 2. Available at: http://www.nccn.org/professionals/physician_gls/PDF/thyroid.pdf; 2007.
- [94] Son Y-I, Jeong H-S, Baek C-H, et al. Extent of prophylactic lymph node dissection in the central neck area of the patients with papillary thyroid carcinoma: comparison of limited versus comprehensive lymph node dissection in a 2-year safety study. *Ann Surg Oncol* 2008;15:2020–6.
- [95] Kim JM, Kim TY, Kim WB, Gong G, Kim SC, Hong SJ, et al. Lymphovascular invasion is associated with lateral cervical lymph node metastasis in papillary thyroid carcinoma. *Laryngoscope* 2006;116:2081–5.
- [96] Roh JL, Kim JM, Park C. Central cervical nodal metastasis from papillary thyroid microcarcinoma: pattern and factors predictive of nodal metastasis. *Ann Surg Oncol* 2008;15: 2482–6.
- [97] Shindo M, Wu JC, Park EE, Tanzella F. The importance of central compartment elective lymph node excision in the staging and treatment of papillary thyroid cancer. *Arch Otolaryngol Head Neck Surg* 2006;132:650–4.
- [98] Cheah K, Arici C, Ituarte PH, Siperstein AE, Duh OY, Clark OH. Complications of neck dissection for thyroid cancer. *World J Surg* 2002;26:1013–6.
- [99] Dijkstra PU, van Wilgen PC, Buijs RP, Brendeke W, de Goede CJ, Kerst A, et al. Incidence of shoulder pain after neck dissection: a clinical explorative study for risk factors. *Head Neck* 2001;23:947–53.
- [100] Cheng PT, Hao SP, Lin YH, Yeh AR. Objective comparison of shoulder dysfunction after three neck dissection techniques. *Ann Otol Rhinol Laryngol* 2000;109:761–6.
- [101] Cappiello J, Piazza C, Giudice M, DeMaria G, Nicolai P. Shoulder disability after different selective neck dissections (levels II–IV versus levels II–V): a comparative study. *Laryngoscope* 2005;115:259–63.
- [102] Kuntz AL, Weymuller Jr EA. Impact of neck dissection on quality of life. *Laryngoscope* 1999;109:1334–8.

- [103] Scheumann GF, Seeliger H, Musholt TF, Gimm O, Wegener G, Dralle H, et al. Completion thyroidectomy in 131 patients with differentiated thyroid carcinoma. *Eur J Surg* 1996;162: 677–84.
- [104] Terrell JE, Welsh DE, Bradford CR, Chepeha DB, Esclamado RM, Hogikyan ND, et al. Pain, quality of life, and spinal accessory nerve status after neck dissection. *Laryngoscope* 2000;110:620–6.
- [105] Inoue H, Nibu K, Saito M, Otsuki N, Ishida H, Onitsuka T, et al. Quality of life after neck dissection. *Arch Otolaryngol Head Neck Surg* 2006;132:662–6.
- [106] van Wilgen CP, Dijkstra PU, van der Laan BF, Plukker JT, Roodenburg JL. Shoulder complaints after neck dissection; is the spinal accessory nerve involved? *Br J Oral Maxillofac Surg* 2003;41:7–11.
- [107] Sobol S, Jensen C, Sawyer W, Costiloe P, Thong N. Objective comparison of physical dysfunction after neck dissection. *Am J Surg* 1985;150:503–9.
- [108] Miccoli P, Materazzi G, Berti P. Minimally invasive video-assisted lateral lymphadenectomy: a proposal. *Surg Endosc* 2008;22:1131–4.
- [109] Lombardi CP, Raffaelli M, Princi P, De Crea C, Bellantone R. Minimally invasive video-assisted functional lateral neck dissection for metastatic papillary thyroid carcinoma. *Am J Surg* 2007;193:114–8.
- [110] Sakorafas GH, Peros G. Sentinel lymph node biopsy in breast cancer; what a clinician should know, a decade after its introduction in clinical practice. *Eur J Cancer Care* 2007;16: 318–21.
- [111] Ariyan CE, Coit DG. Clinical aspects of sentinel lymph node biopsy in melanoma. *Sem Diagn Pathol* 2008;25:86–94.
- [112] Roh J-L, Park C. Sentinel lymph node biopsy as guidance for central neck dissection in patients with papillary thyroid carcinoma. *Cancer* 2008;113:1527–31.
- [113] Rubello D, Pelizzo MR, Al-Nahhas A, Salvatori M, O'Doherty MJ, Guiliano AE, et al. The role of sentinel lymph node biopsy in patients with differentiated thyroid carcinoma. *Eur J Surg Oncol* 2006;32:917–21.
- [114] Pujol P, Daures JP, Nsakala N, Baldet L, Bringer J, Jaffiol C. Degree of thyrotropin suppression as a prognostic determinant in differentiated thyroid cancer. *J Clin Endocrinol Metab* 1996;81:4318–23.
- [115] McGriff NJ, Csako G, Gourgiotis L, Lori CG, Pucini F, Sarlis NJ. Effects of thyroid hormone suppression therapy on adverse clinical outcomes in thyroid cancer. *Ann Med* 2002;34: 554–64.
- [116] Biondi B, Filetti S, Schlumberger M. Thyroid-hormone therapy and thyroid cancer: a reassessment. *Nat Clin Pract Endocrinol Metab* 2005;1(1):32–40.
- [117] Haugen BR, Pacini F, Reiners C, Schlumberger M, Ladenson PW, Sherman SI, et al. A comparison of recombinant human thyrotropin and thyroid hormone withdrawal for the detection of thyroid remnant or cancer. *J Clin Endocrinol Metab* 1999;84:3877–85.
- [118] Burmeister LA, Goumaz MO, Mariash CN, Oppenheimer JH. Levothyroxine dose requirements for thyrotropin suppression in the treatment of differentiated thyroid cancer. *J Clin Endocrinol Metab* 1992;75:344–50.
- [119] Sun L, Davies TF, Blair HC, Abe E, Zaidi M. TSH and bone loss. *Ann N Y Acad Sci* 2006;1068:309–18.
- [120] Sawin CT, Geller A, Wolf PA, Belanger AJ, Baker E, Bacharach P, et al. Low serum thyrotropin concentrations as a risk factor for atrial fibrillation in older persons. *N Engl J Med* 1994;331:1249–52.
- [121] Parle JV, Maisonneuve P, Sheppard MC, Boyle P, Franklyn JA. Prediction of all-cause and cardiovascular mortality in elderly people from one low-serum thyrotropin result: a 10-year cohort study. *Lancet* 2001;358:861–5.
- [122] Surks MI, Ortiz E, Daniels GH, Sawin CT, Col NF, Cobin RH, et al. Subclinical thyroid disease: scientific review and guidelines for diagnosis and management. *JAMA* 2004;291: 228–38.
- [123] Tubiana M, Perez R, Parmentier C, Monnier JP. The survival of patients with thyroid cancers treated with radioactive iodine. Apropos of 147 cases followed up for more than 5 years. *Presse Med* 1968;76:1999–2002.
- [124] Hay ID, Thompson GB, Grant CS, Bergstralh EJ, Dvorak CE, Gorman CA, et al. Papillary thyroid carcinoma managed at the Mayo Clinic during six decades (1940–1999): temporal trends in initial therapy and long-term outcome in 2444 consecutively treated patients. *World J Surg* 2002;26: 879–85.
- [125] Sawka AM, Thephamongkhon K, Brouwers M, Thabane L, Browman G, Gerstein HC. Clinical review 170: a systematic review and metaanalysis of the effectiveness of radioactive iodine remnant ablation for well-differentiated thyroid cancer. *J Clin Endocrinol Metab* 2004;89:3668–76.
- [126] Hay ID, McConahey WM, Goellner JR. Managing patients with papillary thyroid carcinoma: insights gained from the Mayo Clinic's experience of treating 2512 consecutive patients during 1940 through 2000. *Trans Am Clin Climatol Assoc* 2002; 113:241–60.